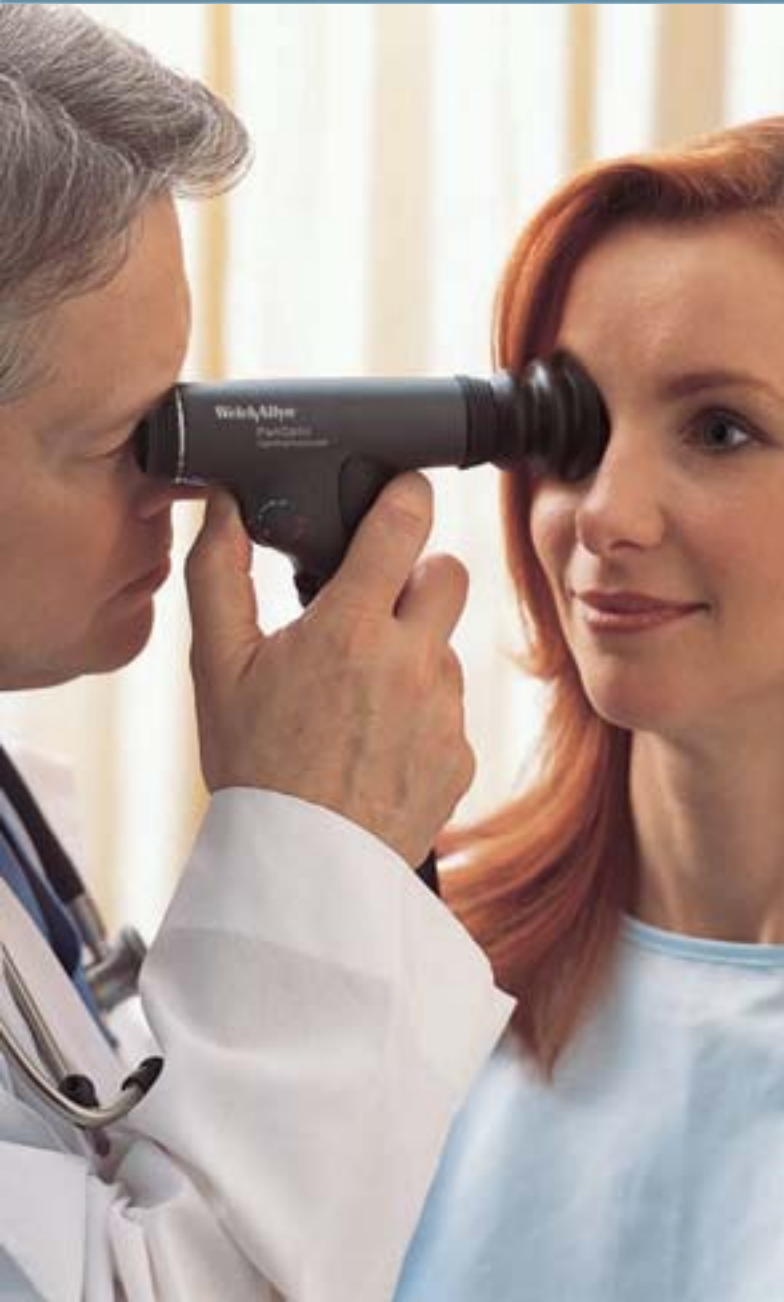

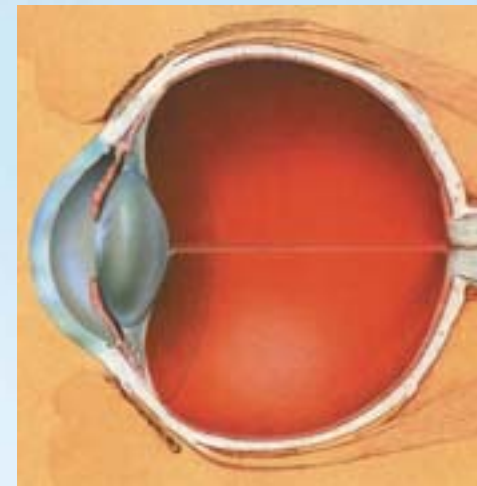
A Guide to the Use of Diagnostic Instruments in Eye and Ear Examinations



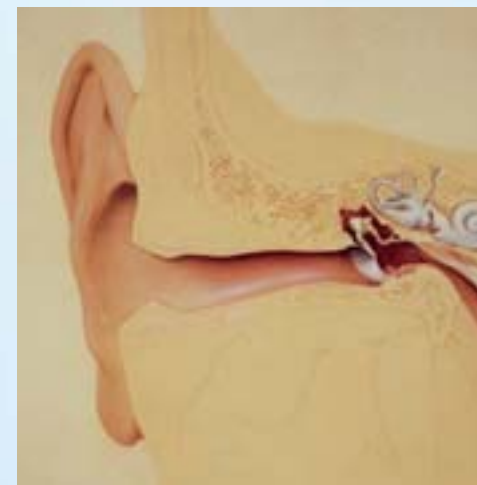WelchAllyn[®]

Advancing Frontline Care[™]

Contents



| | |
|---|----------|
| The Eye | 4 |
| The PanOptic™ Ophthalmoscope | 6 |
| The Coaxial Ophthalmoscope | 7 |
| How to Conduct a PanOptic Ophthalmologic Exam | 8 |
| How to Conduct a Coaxial Ophthalmologic Exam | 10 |
| Common Pathologies of the Eye | 12 |



| | |
|---|-----------|
| The Ear | 18 |
| The Otoscope | 20 |
| How to Conduct an Otoscopic Examination | 22 |
| Pneumatic Otoscopy | 24 |
| Common Pathologies of the Ear | 25 |
| Other Ear Care Products | 31 |

Sponsored by



About Welch Allyn: Welch Allyn, Inc. was founded in 1915 and is today a leading manufacturer of innovative medical diagnostic and therapeutic devices, cardiac defibrillators, patient monitoring systems, and miniature precision lamps. Headquartered in Skaneateles Falls, New York, USA, Welch Allyn employs more than 2,300 people and has numerous manufacturing, sales, and distribution facilities located throughout the world. Additional information on Welch Allyn and its products may be found at www.welchallyn.com.

The Eye

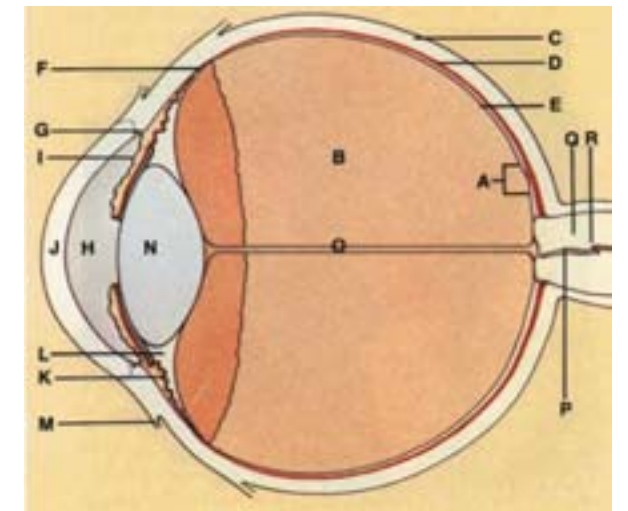
Transparency of the cornea, lens and vitreous humor permits the practitioner to directly view arteries, veins, the optic nerve and the retina.

Direct observation of the structures of the fundus through an effective ophthalmoscope may show disease of the eye itself or may reveal abnormalities indicative of disease elsewhere in the body. Among the most important of these are vascular changes due to diabetes or hypertension and swelling of the optic nerve head due to papilledema or optic neuritis. In this sense, the eye serves as a window through which many valuable clinical evaluations may be made.

When a preliminary diagnosis of an imminently dangerous eye condition, such as acute glaucoma or retinal detachment, is made by the examiner, prompt referral to an ophthalmologist may prevent irreversible damage. Or, when distressing but less urgent conditions, such as visual impairment due to cataract or vitreous floaters are recognized, the patient can be reassured and referred.

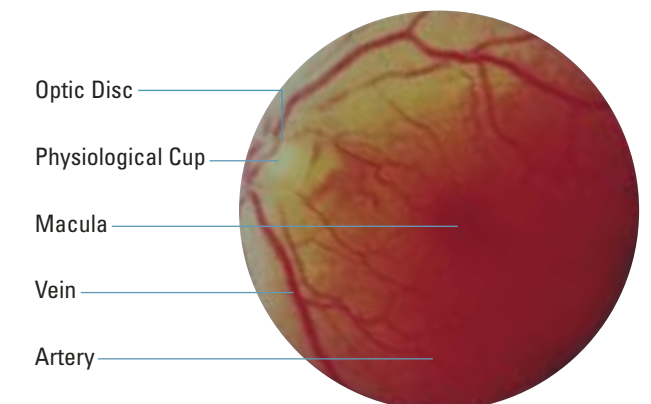
Welch Allyn ophthalmoscopes, with their bright, white halogen illumination coupled with their patented optical systems, allow the examiner to clearly see these important structures of the eye to aid in making the correct diagnosis.

Little has been written giving the practitioner detailed instructions on the use of the ophthalmoscope. Because the examination can give so much information about a patient's well being, correct use of the ophthalmoscope makes it one of the most valuable tools available for diagnostic use. The following pages in this section contain information on ophthalmoscopes, how to conduct an ophthalmic exam, and what to look for while examining the eye.



- | | |
|----------------------|----------------------------------|
| A - Macula | J - Cornea |
| B - Vitreous Humor | K - Ciliary Body |
| C - Sclera | L - Zonule (Suspensory Ligament) |
| D - Choroid | M - Conjunctiva |
| E - Retina | N - Lens |
| F - Ora Serrata | O - Hyaloid Canal |
| G - Canal of Schlemm | P - Central Retinal Vein |
| H - Anterior Chamber | Q - Optic Nerve |
| I - Iris | R - Central Retinal Artery |

NORMAL FUNDUS



PanOptic™ Ophthalmoscope

The Welch Allyn PanOptic Ophthalmoscope incorporates a patented* Axial PointSource™ optical system. The optics system converges the light to a point at the cornea, which allows the practitioner easy entry into small pupils. The illumination pathway then diverges to the retina, illuminating a very wide area of the fundus. The viewing system enables the operator to view the illuminated area on virtually the same axis, thus creating the widest field of view attainable in undilated ophthalmoscopy.

The PanOptic has a focusing range from -20 to +20 diopters. The Dynamic Focusing Wheel adjusts the focus in a continuous, smooth action for more precise control and optimum view. This helps compensate for patient or examiner refractive error, the position of the ophthalmoscope and the changes in viewing requirements necessitated by focusing on different points within the eye.

The patient side eyecup helps the practitioner establish and maintain the proper viewing distance and provides stabilization for the view during the exam. It also serves as the pivoting point for leverage in panning around the retina. While in contact with the patient, the eyecup occludes ambient light, eliminating interference from other light sources.

ADDITIONAL USES FOR THE PANOPTIC OPHTHALMOSCOPE

In addition to examination of the fundus, the ophthalmoscope is a useful diagnostic aid in studying other ocular structures. The light beam can be used to illuminate the cornea and the iris for detecting foreign bodies in the cornea and irregularities of the pupil.

The PanOptic Ophthalmoscope features a Cobalt Blue Filter and add-on Corneal Viewing Lens (model 11820 only), which together can be used along with fluorescein dye applied to the cornea to look for abrasions and foreign bodies on the cornea.

To attach the Corneal Viewing Lens:

1. Remove the patient eyecup.
2. Push and twist on the lens in place of the eyecup, until the bottom's ribs catch.

Refer to pages 8 and 9 to learn how to conduct an ophthalmic exam with the PanOptic ophthalmoscope.

*U.S. PATENT NOS. 6,637,882; 6,527,390



Coaxial Ophthalmoscope

Welch Allyn Coaxial ophthalmoscopes incorporate a patented* coaxial optical system, allowing the axis of illumination to be coincidental with the axis of vision into the retina, thereby eliminating annoying shadows and facilitating examination through virtually any size pupil or vitreous disorder. The fundus and interior anatomy of the eye are viewed with precision and clarity.

Welch Allyn scopes offer a wide choice of 28 viewing lenses, ranging from -25 to +40 diopters, with fast, accurate one-hand selection. This helps compensate for patient or examiner refractive error, the position of the ophthalmoscope and the changes in viewing requirements necessitated by focusing on different points within the eye.

Some coaxial models offer an additional crossed linear polarizing filter/red-free filter switch that increases the versatility of this instrument. When used in conjunction with available apertures, the coaxial ophthalmoscope yields 15 possible apertures.

The illuminated lens dial enables the practitioner to check the lens being used for a particular examination even in a darkened examination room.

The brow rest allows the practitioner to use his/her own eyeglasses comfortably and safely. It also steadies the instrument while in use.

ADDITIONAL USES FOR THE COAXIAL OPHTHALMOSCOPE

In addition to examination of the fundus, the ophthalmoscope is a useful diagnostic aid in studying other ocular structures. The light beam can be used to illuminate the cornea and the iris for detecting foreign bodies in the cornea and irregularities of the pupil.

Refer to pages 10 and 11 to learn how to conduct an ophthalmic examination with the Coaxial ophthalmoscope.

When used correctly and regularly, the Welch Allyn ophthalmoscope is one of the most effective diagnostic instruments available.

*U.S. PATENT NOS. 4,998,818; 4,526,449



APERTURES AND FILTERS

There is a wide range of practical apertures and filters to select from on both the PanOptic and Coaxial ophthalmoscopes: small spot, large spot, micro spot, slit aperture, red-free filter, cobalt blue filter, half-moon, and fixation aperture. This selection of apertures covers all the practitioner's basic needs in an ophthalmoscope.



Small Aperture: Provides easy view of the fundus through an undilated pupil. Always start the examination with this aperture and proceed to micro aperture if pupil is particularly small and/or sensitive to light.



Large Aperture: Standard aperture for dilated pupil and general examination of the eye.



Micro Spot Aperture: Allows easy entry into very small, undilated pupils.



Slit Aperture: Helpful in determining various elevations of lesions, particularly tumors and edematous discs.



Half-Moon Aperture (PanOptic Model 11810 only): Provides a combination of depth perception and field of view.



Fixation Aperture (Coaxial Model only): The pattern of an open center and thin lines permits easy observation of eccentric fixation without masking the macula.



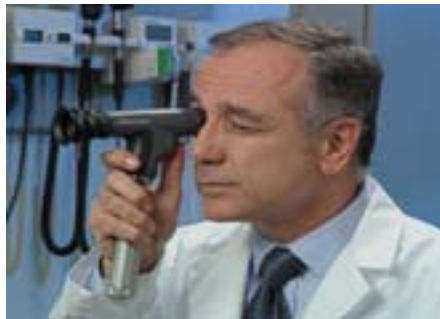Cobalt Blue Filter: Blue filter used with fluorescein dye permits easy viewing of small lesions, abrasions, and foreign objects.



Red-Free Filter: Excludes red rays from examination field for easy identification of veins, arteries, and nerve fibers.

How to Conduct an Ophthalmologic Examination with the PanOptic™ Ophthalmoscope

The following steps will help the practitioner obtain satisfactory results with the PanOptic Ophthalmoscope:



1. Take the PanOptic ophthalmoscope in your right hand with the Practitioner's Side facing you and place your thumb on the Focusing Wheel. Hold the instrument up to your right eye and look through the eyepiece. By rotating the Focusing Wheel with your thumb, focus the instrument on an object approximately 20 feet away.

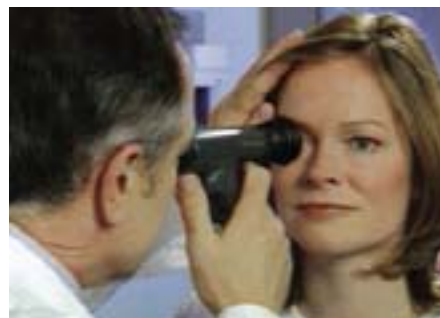

2. Set the Aperture/Filter Dial to the small spot (green line).



3. Dim the room lights. Instruct the patient to look straight ahead at a distant object.

4. Hold the PanOptic up to your eye and position the ophthalmoscope about 6 inches (15 cm) in front and at a slight angle (15 to 20 degrees) on the temporal side of the patient. Direct the light beam into the pupil. A red "reflex" should appear as you look through the pupil.



5. Rest your left hand on the patient's forehead and hold the upper lid of the eye near the eyelashes with your thumb. While the patient is fixating on the specified object, keep the red "reflex" in view and slowly move toward the patient. Follow the red reflex into the pupil until the PanOptic eyecup rests on the orbit of the patient's eye. The trip from 6 inches away to making contact must be one that is slow, deliberate, and steady.

The optic disc should come into view when you are about 1 to 2 inches (3-5 cm) from the patient. Gentle compression of the eyecup will maximize the field of view.

If the optic disc is not focused clearly, rotate the Dynamic Focusing Wheel with your thumb until the optic disc is as clearly visible as possible. The hyperopic, or far-sighted, eye requires more "plus" (rotation towards green) focus for clear focus of the fundus; the myopic, or near-sighted, eye requires "minus" (rotation towards red) focus for clear focus.

If you lose the view of the optic disc while approaching the patient's eye, pull back slowly, relocate the red reflex, and try again.

6. Now examine the disc for clarity of outline, color, elevation and condition of the vessels. Follow each vessel as far to the periphery as you can.

7. To view the macula, instruct your patient to look directly into the light of the ophthalmoscope. This will automatically place the macula in full view. An alternative technique is to have your patient fixate straight ahead. Attain the red reflex from a 15° angle at 6 inches away from the patient's eye. When the PanOptic is 3 inches from contact, instruct the patient to look into the light while the patient is still facing straight ahead. Continue moving towards the patient until the eyecup reaches the orbit of the patient.

Look for abnormalities in the macula area. The red-free filter facilitates viewing of the center of the macula.

8. To examine the extreme periphery, instruct the patient to fixate straight ahead while performing the examination. Pivot around the eye by leveraging the eyecup against the orbit of the patient's eye to achieve the desired view. It is important to compress the eyecup to maximize this technique. Without full compression, the chances of losing your view increase significantly.

This routine will reveal almost any abnormality that occurs in the fundus.

9. To examine the left eye, repeat the procedure outlined above.



ADDITIONAL EXAMS WITH THE PANOPTIC OPHTHALMOSCOPE

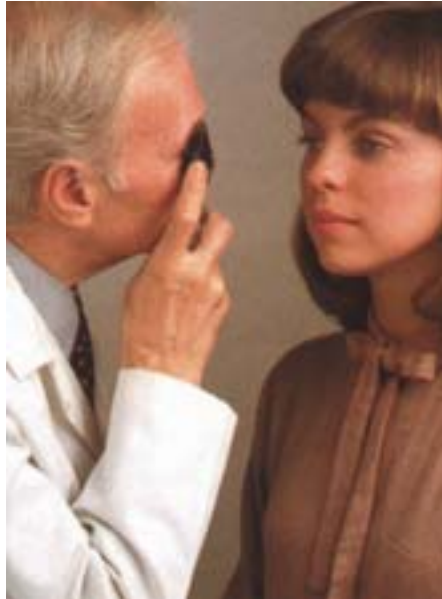To look for abrasions and foreign bodies on the cornea with the corneal viewing lens, no contact is made between the ophthalmoscope and the patient.

Begin the exam about 6 inches from the patient with the focus wheel in the neutral position.

Look through the scope at the patient's cornea to direct the light at the target area.

Adjust the focus wheel into the green (plus) diopters while moving slightly in (closer) or out (further) until a comfortable working distance and magnification of the cornea are achieved.

How to Conduct an Ophthalmologic Examination with a Coaxial Ophthalmoscope



Position the ophthalmoscope about 6 inches (15 cm) in front and 25° to the right side of the patient.

In order to conduct a successful examination of the fundus, the examining room should be either semidarkened or completely darkened. It is preferable to dilate the pupil when there is no pathologic contraindication, but much information can be obtained through the undilated pupil.

The following steps will help the practitioner obtain satisfactory results:

1. For examination of the right eye, sit or stand at the patient's right side.
2. Select "0" on the illuminated lens disc of the ophthalmoscope and start with the small aperture.
3. Take the ophthalmoscope in the right hand and hold it vertically in front of your own right eye with the light beam directed toward the patient and place your right index finger on the edge of the lens dial so that you will be able to change lenses easily if necessary.
4. Dim room lights. Instruct the patient to look straight ahead at a distant object.
5. Position the ophthalmoscope about 6 inches (15 cm) in front and slightly to the right (25°) of the patient and direct the light beam into the pupil. A red "reflex" should appear as you look through the pupil.
6. Rest your left hand on the patient's forehead and hold the upper lid of the eye near the eyelashes with the thumb. While the patient is fixating on the specified object, keep the "reflex" in view and slowly move toward the patient. The optic disc should come into view when you are about 1 to 2 inches (3-5 cm) from the patient. If it is not focused clearly, rotate lenses with your index finger until the optic disc is as clearly visible as possible. The hyperopic, or far-sighted, eye requires more "plus" (green numbers) lenses for clear focus of the fundus; the myopic, or near-sighted, eye requires "minus" (red numbers) lenses for clear focus.
7. Now examine the disc for clarity of outline, color, elevation and condition of the vessels. Follow each vessel as far to the periphery as you can. To locate the macula, focus on the disc, then move the light approximately 2 disc diameters temporally. You may also have the patient look at the light of the ophthalmoscope, which will automatically place the macula in full view. Look for abnormalities in the macula area. The red-free filter facilitates viewing of the center of the macula.

8. To examine the extreme periphery, instruct the patient to:

- Look up for examination of the superior retina
- Look down for examination of the inferior retina
- Look temporally for examination of the temporal retina
- Look nasally for examination of the nasal retina.

This routine will reveal almost any abnormality that occurs in the fundus.

9. To examine the left eye, repeat the procedure outlined above but hold the ophthalmoscope in your left hand, stand at the patient's left side and use your left eye.

OVERCOMING CORNEAL REFLECTION

One of the most troublesome barriers to a good view of the retina is the light reflected back into the examiner's eye from the patient's cornea—a condition known as corneal reflection. There are three ways to minimize this nuisance:

- The Coaxial ophthalmoscope features a crossed linear polarizing filter that may be used. The filter reduces corneal reflection by 99%. It is recommended that the polarizing filter be used when corneal reflection is present.
- Use the small aperture. However, this reduces the area of the retina illuminated.
- Direct the light beam toward the edge of the pupil rather than directly through its center. This technique can be perfected with practice.

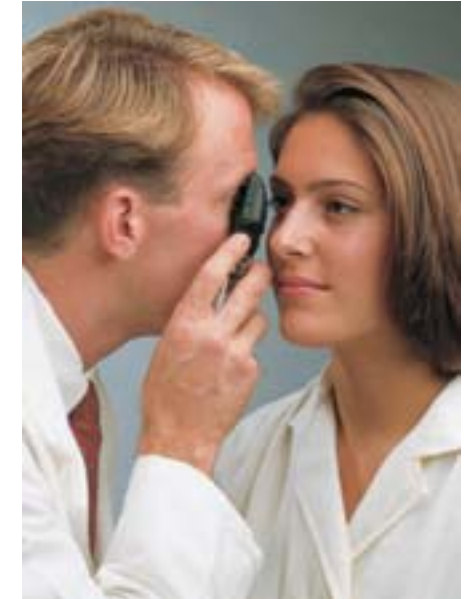
USE OF FIXATION TARGET

Direct the patient to focus on the center of the fixation target projected within the light beam. Simultaneously check the location of the pattern on the fundus. If the center of the pattern does not coincide with the macula, eccentric fixation is indicated. In this procedure, the crossed linear polarizing filter is especially useful since it dramatically reduces reflections caused by the direct corneal light path.

ADDITIONAL EXAMS WITH COAXIAL OPHTHALMOSCOPE

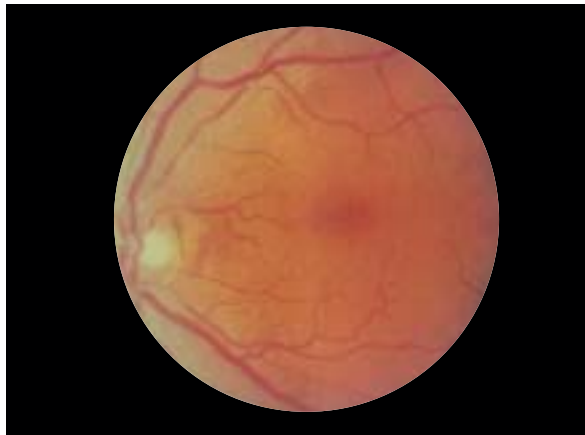
By selecting the +15 lens in the scope and looking at the pupil as in a fundus examination [2 inches (5 cm) distance from the patient], the examiner may verify doubtful pupillary action.

One can also easily detect lens opacities by looking at the pupil through the +6 lens setting at a distance of 6 inches (15 cm) from the patient. In the same manner, vitreous opacities can be detected by having the patient look up and down, to the right and to the left. Any vitreous opacities will be seen moving across the pupillary area as the eye changes position or comes back to the primary position.



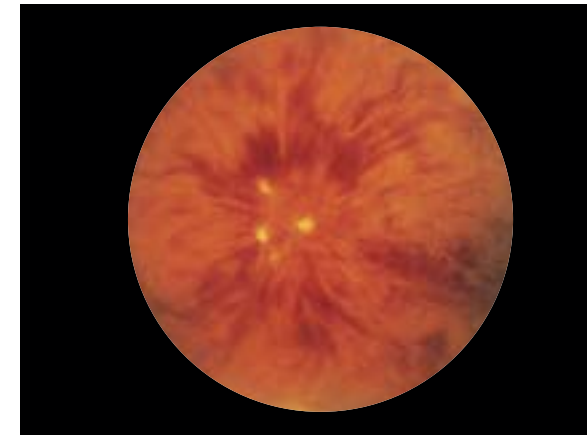
Examine the disc for clarity of outline, color, elevation and condition of the vessels (Step 7).

Common Pathologies of the Eye



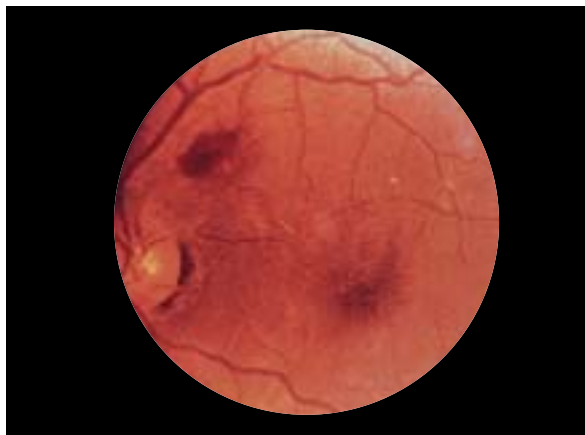
NORMAL FUNDUS

- Disc: Outline clear; central physiological cup is pale
- Retina: Normal red/orange color, macula is dark; avascular area temporally
- Vessels: Arterial/venous ratio 2 to 3; the arteries appear a bright red, the veins a slightly purplish color



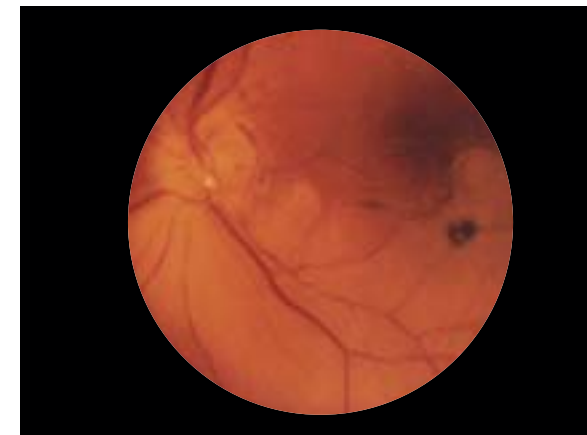
CENTRAL RETINAL VEIN OCCLUSION

- Disc: Virtually obscured by edema and hemorrhages
- Retina: Extensive blot retinal hemorrhages in all quadrants to periphery
- Vessels: Dilated tortuous veins; vessels partially obscured by hemorrhages



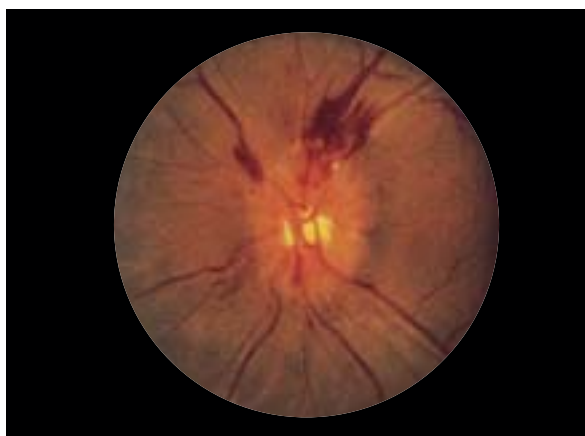HYPERTENSIVE RETINOPATHY

- Disc: Outline clear
- Retina: Exudates and flame hemorrhages
- Vessels: Attenuated arterial reflex



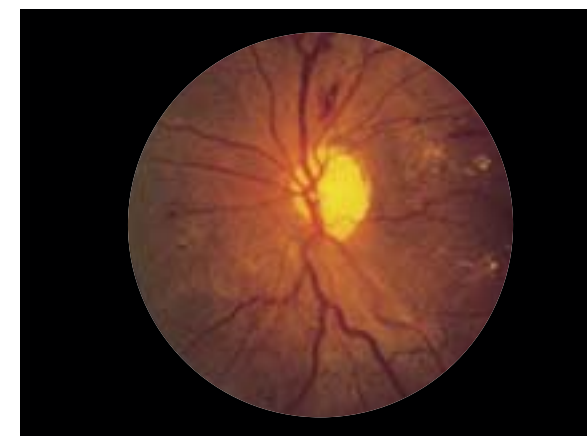
INFERIOR BRANCH RETINAL ARTERY OCCLUSION DUE TO EMBOLUS

- Disc: Prominent embolus at retinal artery bifurcation
- Retina: Inferior retina shows pale, milky edema; superior retina is normal
- Vessels: Inferior arteriole tree greatly attenuated and irregular; superior vessel is normal



HYPERTENSIVE RETINOPATHY (ADVANCED MALIGNANT)

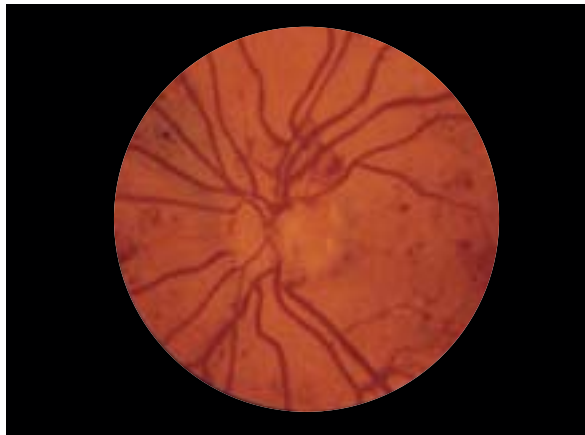- Disc: Elevated, edematous disc; blurred disc margins
- Retina: Prominent flame hemorrhages surrounding vessels near disc border
- Vessels: Attenuated retinal arterioles



NONPROLIFERATIVE DIABETIC RETINOPATHY

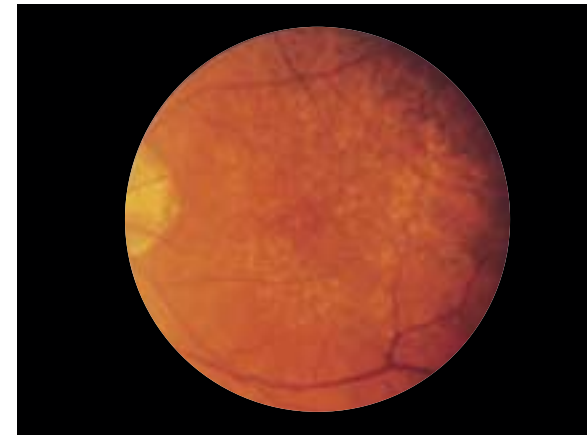
- Disc: Normal
- Retina: Numerous scattered exudates and hemorrhages
- Vessels: Mild dilation of retinal veins

Common Pathologies of the Eye



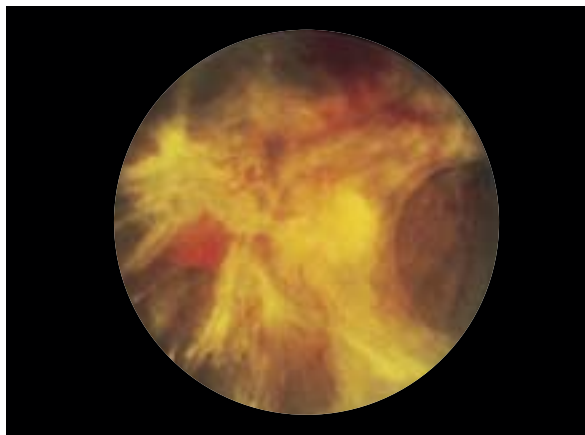
PROLIFERATIVE DIABETIC RETINOPATHY

- Disc: Net of new vessels growing on disc surface
- Retina: Numerous hemorrhages, new vessels at superior disc margin
- Vessels: Dilated retinal veins



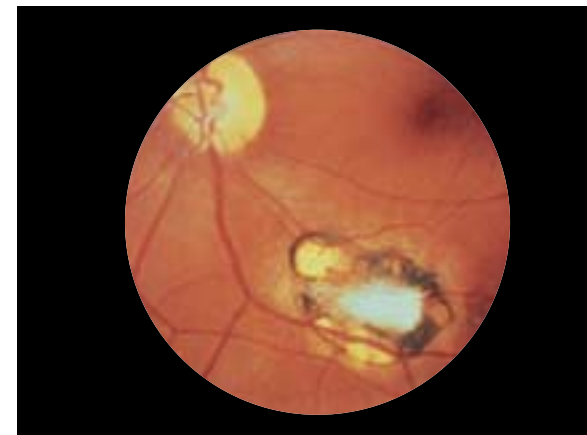
MACULAR DRUSEN (COLLOID BODIES)

- Disc: Normal
- Retina: Extensive white drusen of the retina
- Vessels: Normal



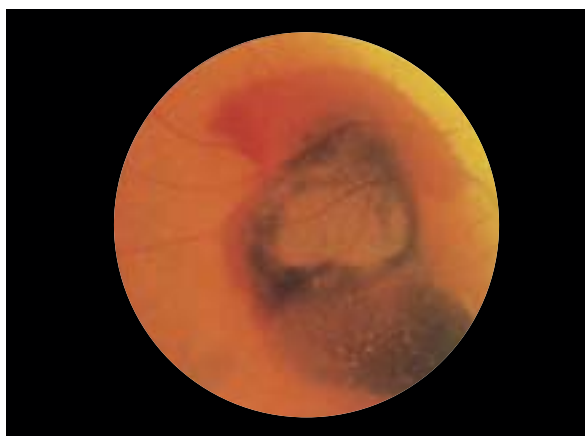
END STAGE DIABETIC RETINOPATHY

- Disc: Partially obscured by fibrovascular proliferation
- Retina: Obscured by proliferating tissue; small area of retina with hemorrhage seen through "window" of fibrovascular membrane
- Vessels: Abnormal new vessels in fibrous tissue
- Vitreous: Prominent fibrovascular tissue



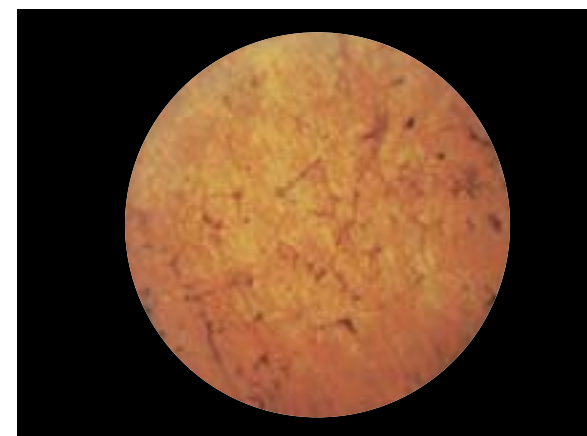
INACTIVE CHORIORETINITIS (TOXOPLASMAS)

- Disc: Normal
- Retina: Well-circumscribed lesion with areas of hyperpigmentation and atrophy of retina, white sclera showing through
- Vessels: Normal



ADVANCED HEMORRHAGIC MACULAR DEGENERATION

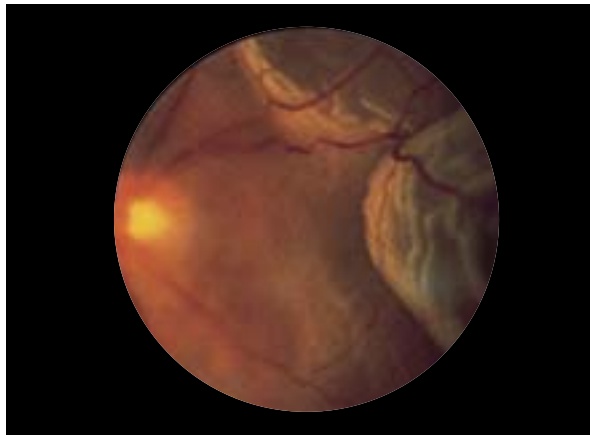
- Disc: Normal
- Retina: Large macular scar with drusen; prominent macular hemorrhage
- Vessels: Normal



ADVANCED RETINITIS PIGMENTOSA

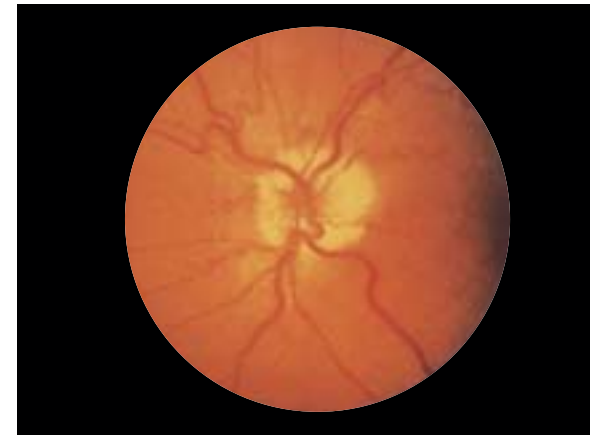- Disc: Normal
- Retina: Scattered retinal pigmentation in classic bone spicule pattern
- Vessels: Greatly attenuated

Common Pathologies of the Eye



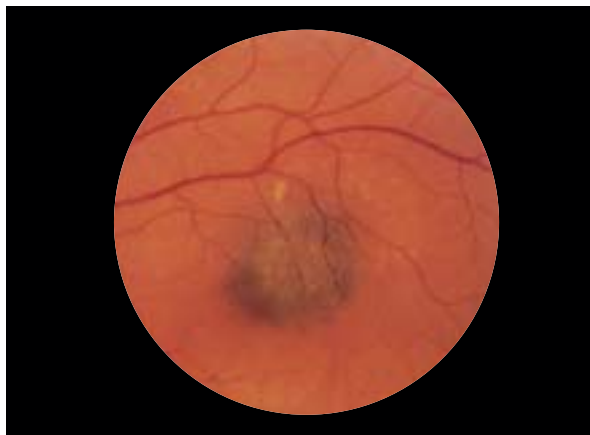
RETINAL DETACHMENT

- Disc: Normal
- Retina: Gray elevation in temporal area with folds in detached section
- Vessels: Tortuous and elevated over detached retina



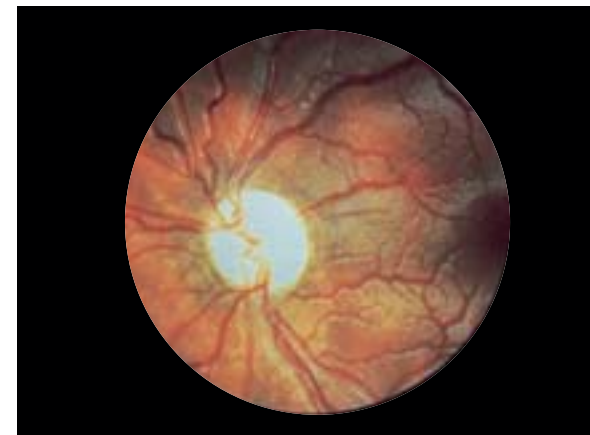
OPTIC NEURITIS

- Disc: Elevated with blurred margins
- Retina: Mild peripapillary edema
- Vessels: Mild dilation of vessels on disc



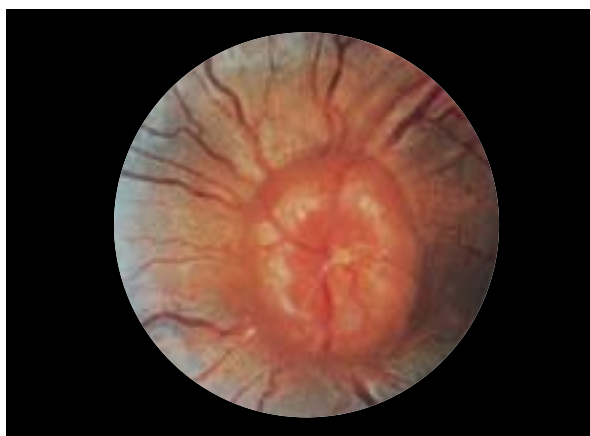BENIGN CHOROIDAL NEVUS

- Disc: Normal
- Retina: Slate gray, flat lesion under retina; several drusen overlying nevus
- Vessels: Normal



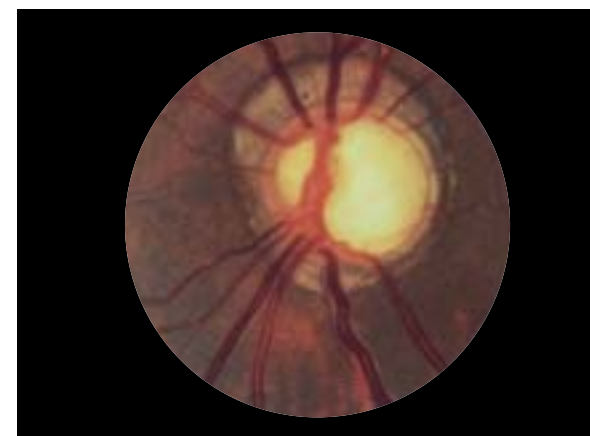
OPTIC ATROPHY

- Disc: Margins sharp and clear; pale white color
- Retina: Normal
- Vessels: Arteries attenuated; veins normal



PAPILLEDEMA

- Disc: Elevated, edematous disc; blurred disc margins; vessels engorged
- Retina: Flame retinal hemorrhage close to disc
- Vessels: Engorged tortuous veins



GLAUCOMATOUS CUPPING OF DISC

- Disc: Large cup, disc vessels displaced peripherally; pale white color; pigment ring surrounding disc
- Retina: Normal
- Vessels: Normal

The Ear

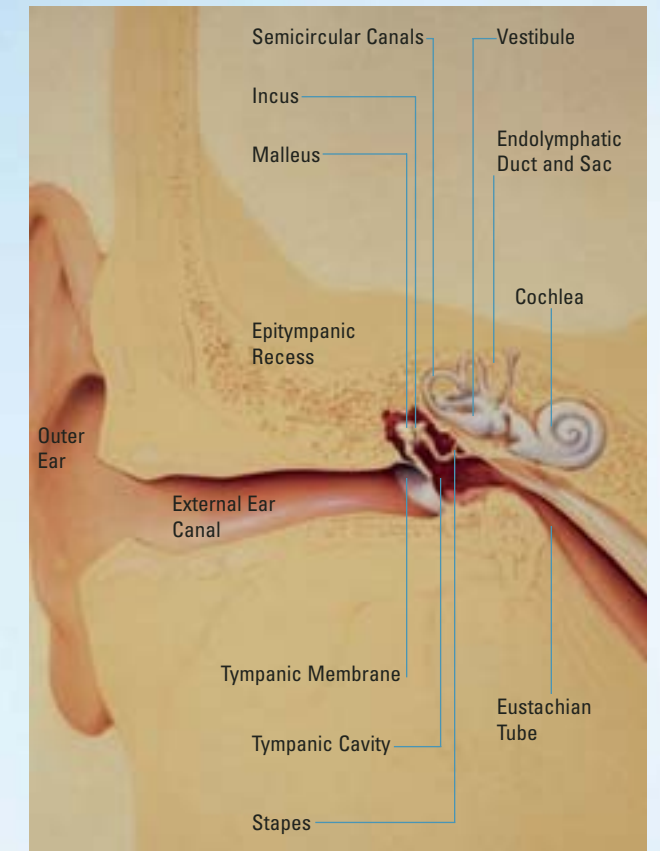
Since symptoms of ear disease are relatively few in number and frequently nonspecific, a clinical examination of the ear is important in the management of ear disorders.

When a patient complains of ear pain, examination of the ear is indicated to differentiate whether the patient's disorder is an ear infection or a disorder originating in adjacent structures, such as the temporomandibular joint, the teeth or the tonsils. As the only window into the middle ear, the appearance and behavior of the tympanic membrane offer valuable information about possible disease within the middle ear.

Fortunately, the ear provides easy access for examining and diagnosing disorders of the complex and interrelated ear, nose and throat system. The Welch Allyn otoscope, when used correctly, is the single most important diagnostic tool available to the practitioner for determining whether the ear is the source of the patient's complaint.

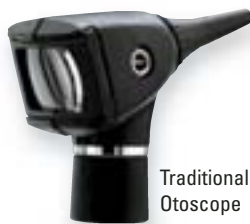Otoscopy is one of the primary methods a practitioner uses for diagnosing patient complaints for the entire ear-nose-throat complex. Use of a well-designed otoscope which provides illumination, magnification and air pressure capability for checking tympanic membrane mobility is, therefore, essential, allowing the practitioner to view the ear canal and, in particular, the tympanic membrane with clarity.

The examination instructions that follow this section use the Welch Allyn otoscope, which incorporates many features that aid in achieving an accurate, thorough examination.



MacroView™ Otoscope

The Welch Allyn MacroView otoscope features a patented optical system that provides the practitioner with an increased field of view and magnification to get a large, clear image of the tympanic membrane. Welch Allyn's traditional diagnostic otoscopes feature a wide-angle magnified viewing lens.



Traditional Otoscope

Fiber optics and halogen light produce optimum illumination

The Welch Allyn otoscope uses both fiber optic technology and Halogen HPX™ illumination. Fiberoptic light transmission provides a 360° ring of light without visual obstruction or specular reflection. This distal light results in glare-free viewing and an easier examination.

Focusing capability (MacroView Otoscope Only)

The Welch Allyn MacroView otoscope has the capability to zoom in or out on the area in view, resulting in a clearer image to aid in diagnosis. A focusing wheel, conveniently located on each side of the otoscope and the back eyepiece, is available to the practitioner for adjusting the focal length. The adjustable focal length can compensate for both the practitioner's vision and the length of the patient's ear canal, thus creating the clearest view of the tympanic membrane possible.

Pneumatic otoscopy capability

When examining tympanic membrane mobility, the ability to perform pneumatic otoscopy is extremely valuable. The Welch Allyn otoscope incorporates a closed system and an airtight seal.

Specula attachment and removal

The Welch Allyn MacroView otoscope features a unique specula attachment and removal design, the TipGrip, which provides the practitioner with a secure attachment between the specula and the otoscope during the exam. After the examination is complete, the tip can be released from the otoscope by turning the TipGrip counterclockwise or by simply twisting off the tip with one hand, as is the technique with traditional otoscope models.

Default Focus: Optimal setting for most ear examinations



MacroView Otoscope with Throat Illuminator

TipGrip: Ensures ear speculum is fastened securely and easily disposed

Insufflation Port: Creates closed system for pneumatic otoscopy to assess middle ear disorders. Apply positive and negative air pressure and view tympanic membrane

Adjustable Focus: Ability to zoom in or out to fine tune view

Throat illuminator: Provides light in a handy built-in penlight

SPECULUM OPTIONS

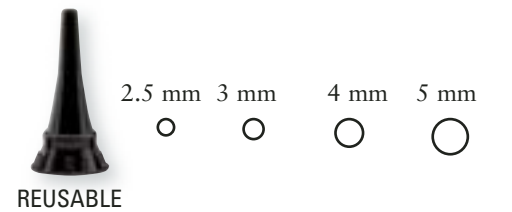
In order to obtain the maximum field of view, the examiner should always select the largest size speculum which fits comfortably into the patient's ear canal.

The following guidelines may be helpful:

| Patient | Size |
|----------|----------------|
| Adults | 4 mm or 5 mm |
| Children | 3 mm or 4 mm |
| Infants | 2.5 mm or 3 mm |

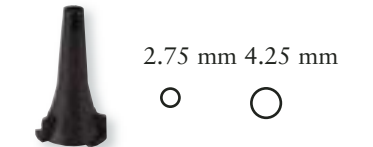
The examiner can choose from several types of specula and specula accessories:

The first type of speculum is reusable and made of lightweight, durable polypropylene. Reusable specula are available in four sizes: 2.5 mm, 3 mm, 4 mm and 5 mm.



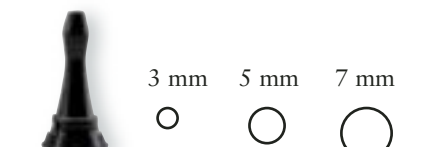
REUSABLE

The second type of speculum is the Universal KleenSpec®, a disposable, economical and convenient tip. KleenSpec tips are made of nontoxic plastic and are available in two sizes: 2.75 mm (pediatric) and 4.25 mm (adult).



KLEENSPEC®

The third type of speculum, available for traditional Welch Allyn otoscopes, is SofSpec®, a reusable specula with a rigid plastic base and a special soft material at the distal end. SofSpec fits snugly into the external ear canal. These specula are available in three sizes: 3 mm, 5 mm, and 7 mm and may be cleaned or sterilized by conventional methods.



SOFSPEC®

For improved seal and comfort during pneumatic otoscopy, the SofSeal™ can be placed on the end of either a disposable or reusable ear speculum. Available in two sizes, the various combinations of the SofSeal and ear specula allow you to optimize the fit for each individual patient's ear canal.



SOFSEAL™

Two sizes fit ear specula ranging from 2 to 5 mm

To perform instrumentation under visualization, the slotted instrumentation tip (compatible with 23810 and 23820 MacroView) is recommended.



SLOTTED SPECULA

How to Conduct an Otoscopic Examination



1. Carefully inspect the pinna and postauricular skin. Gently palpate the pinna to determine if any tenderness exists.
2. Inspect the entrance to the ear canal for debris or pus, which might interfere with further examination.
3. Choose the largest speculum that can comfortably be inserted into the ear canal. Straightening the outer ear canal makes insertion of the speculum easier. For adults, this is accomplished by retracting the pinna upwards and backwards. For children, this is accomplished by retracting the pinna horizontally backwards.
4. When using the MacroView™ otoscope, set the focusing wheel of the otoscope to the default position by aligning the green line on the focusing wheel with the corresponding green dot on the side of the instrument. You will feel the focusing wheel settle into the default setting. The majority of the exams can be completed at the default focusing position.

5. There are two common ways to hold the otoscope. The first way is to hold the otoscope like a hammer by gripping the top of the power handle between your thumb and forefinger, close to the light source. You can conveniently hold the bulb of the pneumatic attachment between the palm of the same hand and the power handle. It is recommended that you extend the middle and ring finger outward so they come into contact with the person's cheek. This way, any sudden flinch by the patient will not cause the otoscope to be jammed into the ear canal.

The otoscope can also be held like a pencil, between the thumb and the forefinger, with the ulnar aspect of the hand resting firmly but gently against the patient's cheek. You can hold the bulb of the pneumatic attachment in the palm of the same hand. If the patient turns or moves, the otoscope will move in unison with the patient's head. This will avoid possible injury to the ear canal or even the tympanic membrane.

It is very important that the otoscope be held correctly, particularly when examining children. A sudden movement by the patient could cause the skin on the inside of the ear canal to be pierced by the end of the speculum.

6. It may be necessary to adjust the line of sight and the position of the speculum to get a complete view of the entire ear canal and all areas of the tympanic membrane. This yields a composite view of the external canal and the tympanic membrane.

7. If the tympanic membrane or desired area in view is not in focus, the practitioner has the option to adjust the focal length of the optics system of the MacroView otoscope. To adjust the focal length, place a finger on either side of the focusing wheel or on the back eyepiece of the otoscope. To shorten the focal length or zoom in, rotate the focusing wheel towards the smaller dashes on the side of the otoscope. To increase the focal length or zoom out, rotate the focusing wheel towards the longer dashes.

8. After the examination is complete, the used specula should be removed from the otoscope. Simply twist the specula off or use the TipGrip feature (MacroView only) by rotating the TipGrip counter-clockwise to disengage the specula.

Pneumatic Otoscopy

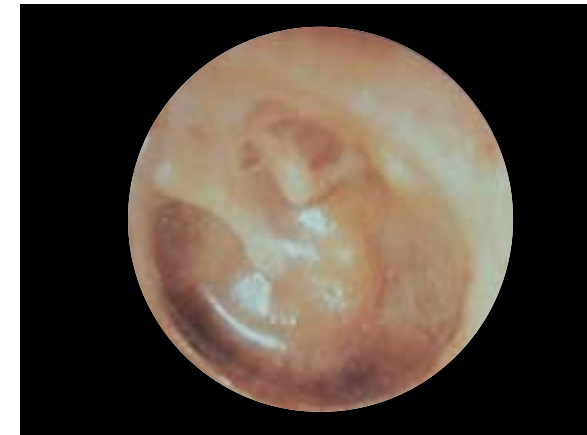Pneumatic otoscopy provides practitioners with a simple method for determining tympanic mobility and helps then recognize many middle ear disorders.

It is the pneumatic capability and insufflator attachment of the otoscope which enable the examiner to assess the mobility of the intact tympanic membrane. This first requires that you use a speculum sufficiently large to fit snugly into the ear canal in order to establish an airtight chamber between the canal and the interior of the otoscope head.

Gently squeezing the insufflator attachment produces small changes in the air pressure of the canal. By observing the relative movements of the tympanic membrane in response to the induced changes in pressure, the practitioner can obtain valuable diagnostic information about the mobility of the tympanic membrane. When fluid is present in the middle ear, for example, movement of the tympanic membrane is generally diminished or absent. The pneumatic otoscope may also be useful in distinguishing between a thin atrophic intact tympanic membrane adherent to the medial wall of the middle ear, which can be made to move, and a large perforation, which will not move. This procedure provides a simple method for determining tympanic membrane mobility and is of value in the recognition of many middle ear disorders.

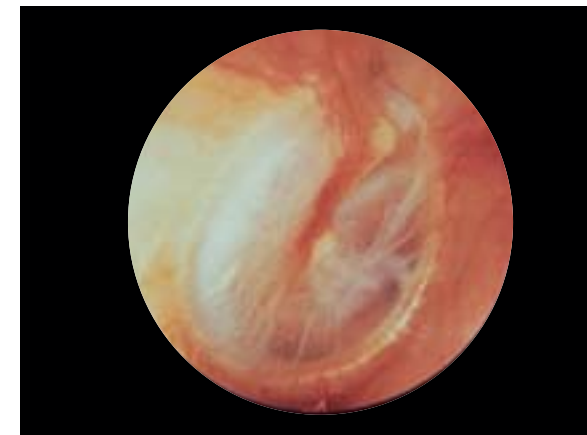


Common Pathologies of the Ear



NORMAL TYMPANIC MEMBRANE (LEFT EAR)

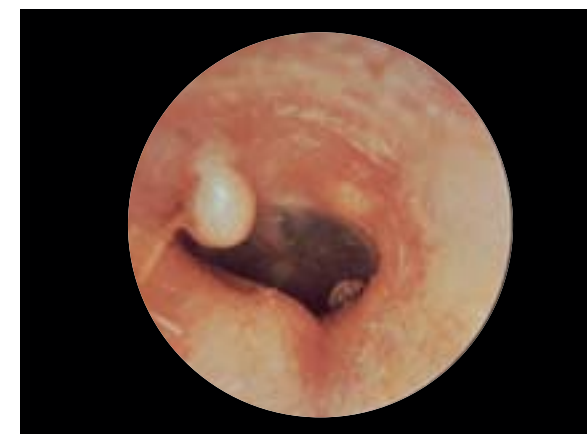The normal tympanic membrane (TM) is a pale, gray, ovoid semitransparent membrane situated obliquely at the end of the bony external auditory canal. The handle of the malleus is seen extending downwards and backwards, ending at the apex of the triangular "cone of reflected light." The long process of the incus and its articulation with the head of the stapes may frequently be seen through the postero-superior quadrant of a thin tympanic membrane. The mobility of an intact TM can readily be assessed by using the pneumatic attachment to the otoscope.



RED REFLEX (RIGHT EAR)

The introduction of a speculum into the external auditory canal may cause a reflex dilatation of the circumferential and manubrial blood vessels supplying the tympanic membrane.

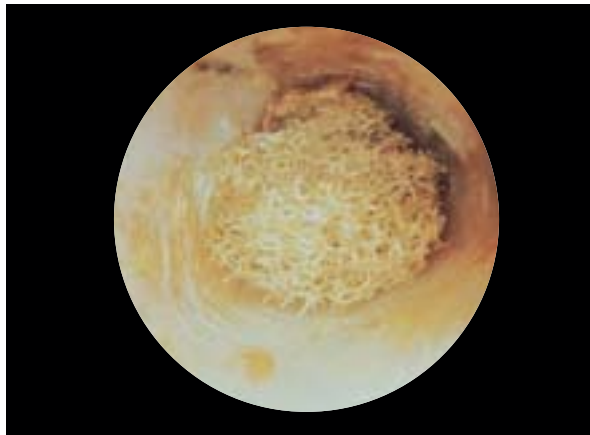
Following a prolonged examination of the ear or in a crying child, this vasodilatation may produce an appearance mimicking that of an early acute otitis media.



EXOSTOSIS (LEFT EAR)

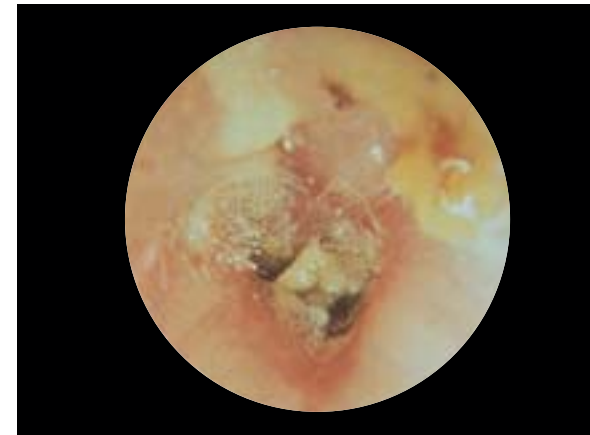
Exostoses appear as discreet, hard, round or oval outcroppings which are sometimes pedunculated. Exostoses in the ear canal are more often multiple than single and are usually bilateral. They are usually asymptomatic, extremely slow growing and seldom enlarge sufficiently to occlude the meatus. Multiple exostoses appear to result from the prolonged stimulation of the bony external canal with cold water and are consequently seen more commonly in persons who swim frequently.

Common Pathologies of the Ear



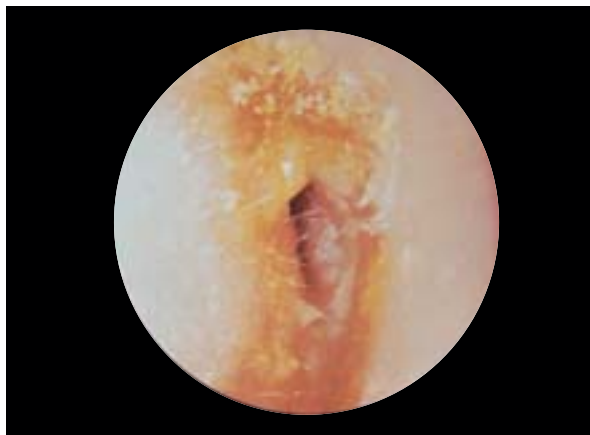
FOREIGN BODY

A varied selection of foreign bodies has been discovered in the ear canals of children. In this case, a large piece of sponge rubber was removed. In adults, a forgotten piece of cotton wool is frequently found. The foreign body or an unsuccessful attempt to remove it can both product secondary otitis externa or damage to the tympanic membrane and ossicles. In young children, it is sometimes safer to administer a short, general anesthetic.



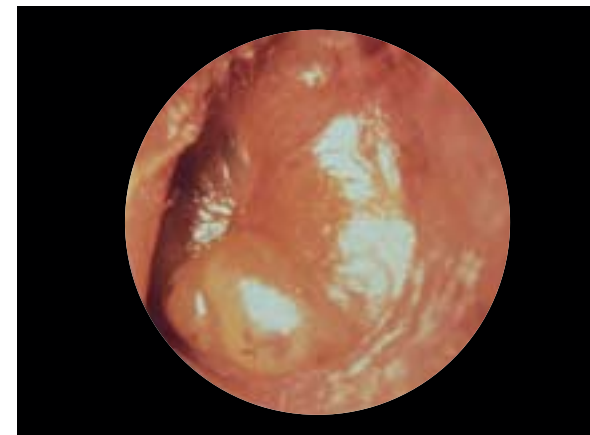
OTOMYCOSIS

Otoscopy examination in cases of otomycosis reveals a white or cream colored, thickish debris which may have a fluffy appearance due to the presence of tiny mycelia. When the infection is caused by *Aspergillus niger*, it may be possible to identify the tiny grayish-black conidiophores. The underlying external canal skin is often inflamed and granular from invasion by fungal mycelia. Otomycosis may follow the use of topical antibiotic ear drops.



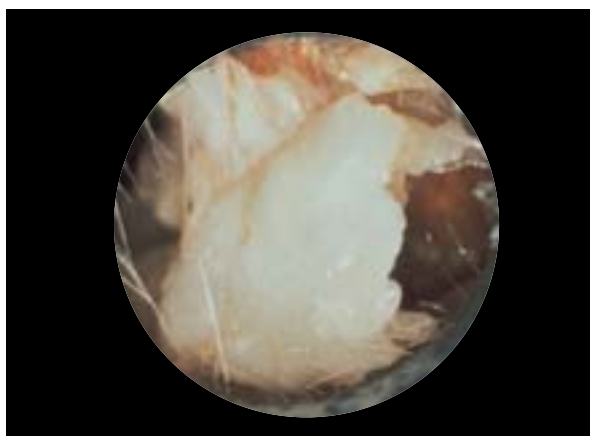
ACUTE OTITIS EXTERNA (LEFT EAR)

Trauma (fingernails, bobby pins, cotton tipped swabs) and moisture (after showering or swimming) are the most common factors responsible for the development of acute diffuse otitis externa. The skin of the ear canal is painful, infected and swollen, and it may be impossible to visualize the tympanic membrane. There is often a considerable amount of keratin debris in the canal which must be removed if local treatment is to be effective. Gram negative and anaerobic bacteria are the most common pathogens; however, a culture of material should be a clinical consideration.



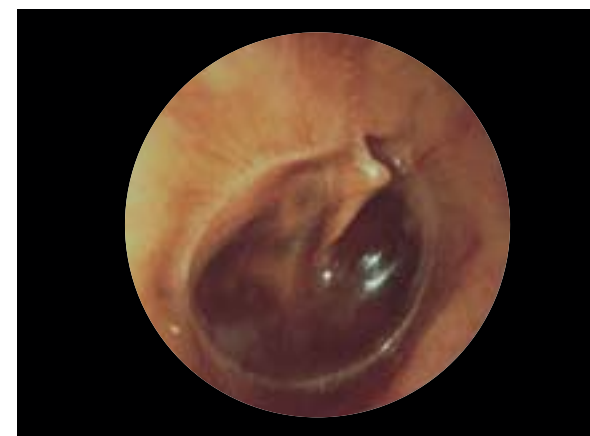
ACUTE OTITIS MEDIA

This acute infection of the middle ear cleft frequently intensifies upper respiratory tract infections and occurs more commonly in children. In the early stages of acute otitis media, the tympanic membrane varies according to the stage of the disease. The tympanic membrane is retracted and pink with dilatation of the manubrial and circumferential vessels. Later, as the disease progresses, the tympanic membrane bulges, becoming fiery red in color and may eventually perforate, releasing pus into the external auditory canal.



KERATOSIS OBTURANS

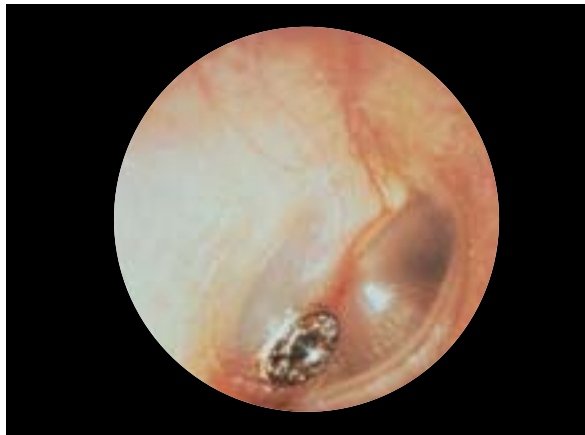In this condition of unknown etiology, the bony meatus is totally occluded by a stony, hard plug of whitish keratin debris. Keratosis obturans is more frequently seen in patients with bronchiectasis and chronic sinusitis. Removal of this material is extremely difficult because of its consistency and its frequent adherence to the underlying canal skin; a general anesthetic may be required in some patients.



SEROUS OTITIS MEDIA (RIGHT EAR)

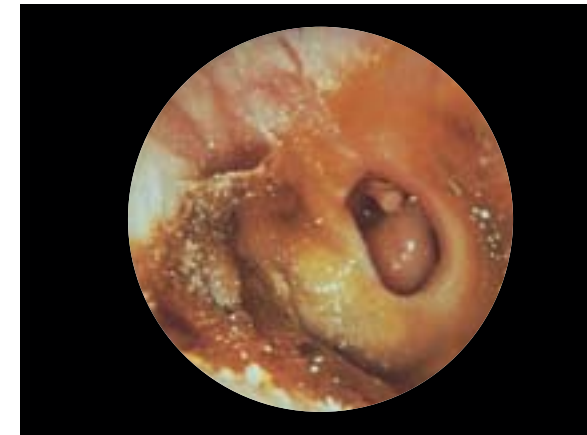
In serous otitis media the tympanic membrane is retracted and shows decreased mobility with pneumatic otoscopy. The handle of the malleus is usually foreshortened, chalky-white in color, and the lateral process is prominent. The presence of a thin, serous effusion within the middle ear gives the tympanic membrane a yellowish or even bluish appearance, and in cases of incomplete eustachian tube obstruction, air bubbles or an air fluid level may be seen.

Common Pathologies of the Ear



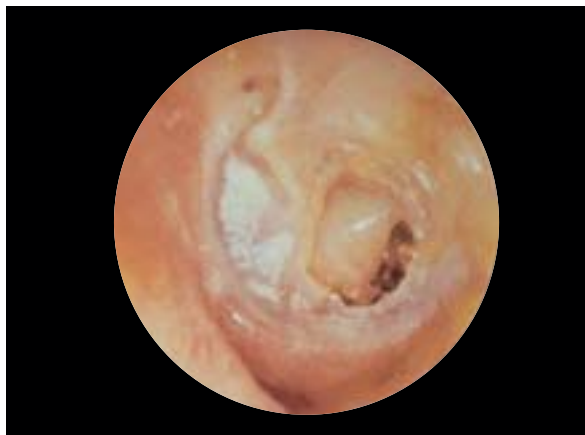
TYMPANOSTOMY TUBE (RIGHT EAR)

A tympanostomy tube is often inserted into the tympanic membrane to ventilate the middle ear in cases of chronic serous otitis media. These tubes come in a variety of sizes, shapes and materials. The tympanostomy tube should be seen to be in place in the tympanic membrane with its lumen patent and free of any exudate or debris.



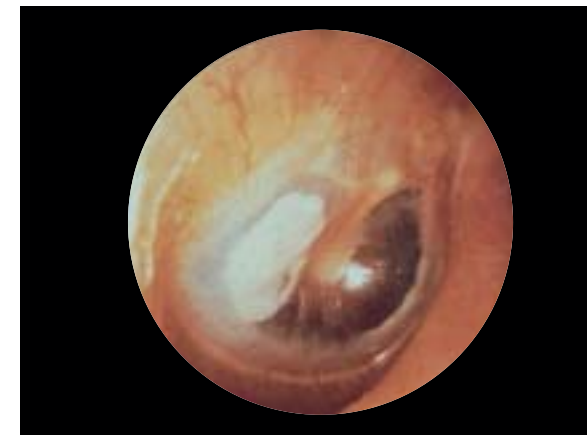
CHRONIC SUPPURATIVE OTITIS MEDIA (LEFT EAR)

Chronic suppurative otitis media is characterized by recurrent painless otorrhea. The discharge may vary from mucoid to frankly purulent. Pseudomonas, Proteus, and Coliforms are the three most commonly isolated bacteria; however, fungal organisms can also coexist.



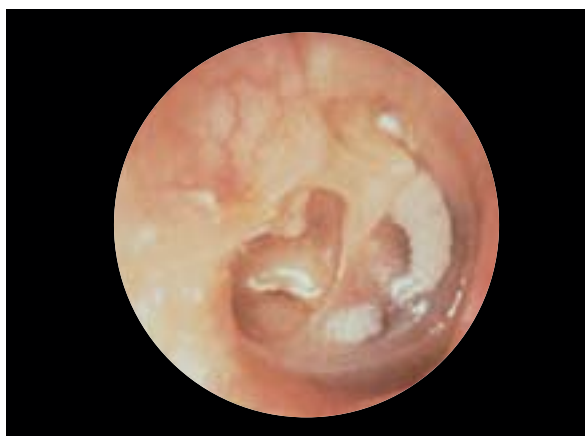
CENTRAL PERFORATION OF THE TYMPANIC MEMBRANE (LEFT EAR)

Perforations of the pars tensa of the tympanic membrane can result from infection or trauma. In this case the large central perforation resulted from repeated middle ear infections.



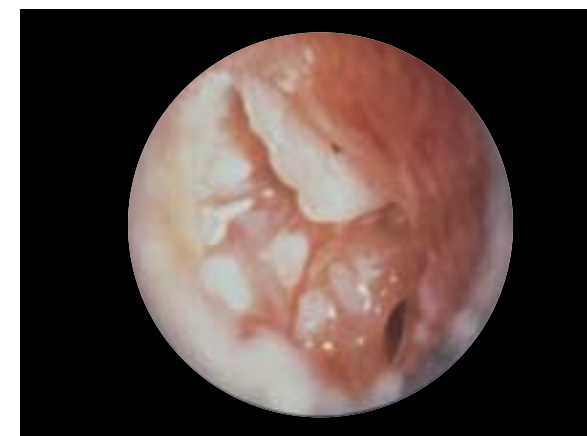
TYMPANOSCLEROSIS (RIGHT EAR)

Tympanosclerotic plaques of varying sizes are seen as chalky white deposits in the tympanic membrane. They occur as a result of a postinflammatory deposition of thickened hyalinized collagen fibrils in the middle fibrous layer of the tympanic membrane and indicate that the patient has had a previous significant ear infection.



HEALED CENTRAL PERFORATION (RIGHT EAR)

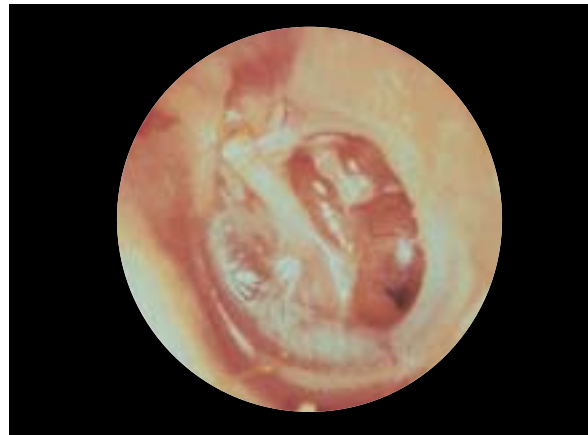
When a large perforation heals, the middle fibrous layer of the tympanic membrane remains deficient so that a thin semi-transparent pseudomembrane resembling an open perforation may be seen. Gentle use of the pneumatic otoscope will, however, demonstrate that the drum is intact. This thinned segment of a healed tympanic membrane lacks the strength of a normal drum and forceful syringing may result in reperforation.



TYMPANOSCLEROSIS INVOLVING THE OSSICLES (LEFT EAR)

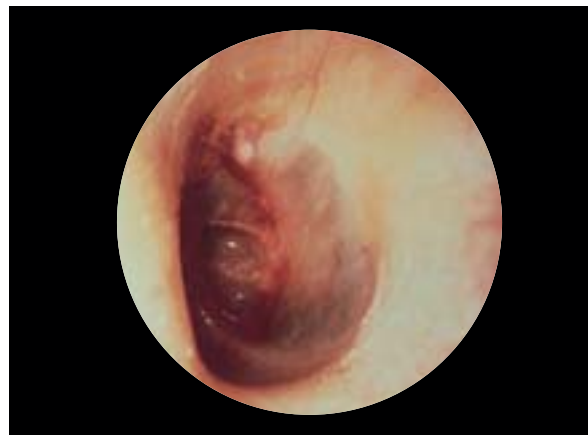Tympanosclerotic plaques may also occur within the middle ear cavity. This photograph shows tympanosclerotic deposits enveloping the incudostapedial joint. A few plaques are also present on the promontory. Partial or total fixation of the ossicular chain by tympanosclerosis is responsible for some cases of acquired conductive hearing loss.

Common Pathologies of the Ear



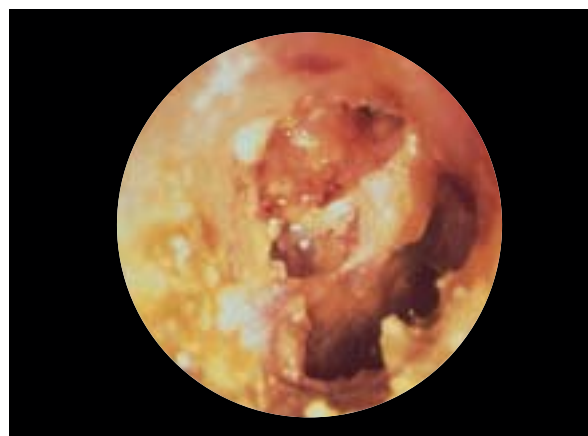
ADHESIVE (ATROPHIC) OTITIS MEDIA (LEFT EAR)

Following long-standing eustachian tube obstruction, the tympanic membrane may become atrophic and retracted onto the medial wall of the middle ear and ossicles, thereby obliterating the middle ear space. In this case, a thin atrophic tympanic membrane is draped over the head of the stapes and the tip of the long process of the incus has been eroded. It can sometimes be difficult to differentiate an atrophic, immobile, retracted tympanic membrane from a large central perforation. In this circumstance, pneumatic otoscopy is often of value.



TRAUMATIC PERFORATION (LEFT EAR)

These perforations result from a variety of causes, including a blow to the ear, blast injury, or the insertion of a cotton tipped swab or bobby pin, but rarely follow forceful syringing. Traumatic perforations generally involve the posterior part of the pars tensa. While traumatic perforations may be of any shape or size, they are usually small with clean-cut edges. Fresh blood may be seen in the deep meatus. Most traumatic perforations heal spontaneously, provided the ear canal is kept clean and dry to prevent secondary infection.



CHOLESTEATOMA (RIGHT EAR)

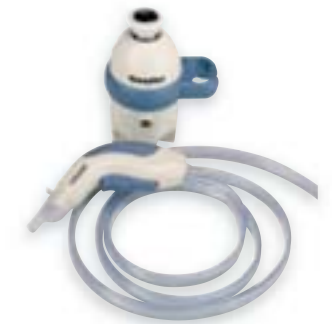A cholesteatoma is a slowly expanding and eroding cyst lined with stratified squamous keratinizing epithelium which invades the middle ear cleft. The presence of whitish keratin debris within a postero-superior perforation indicates the presence of an underlying epidermoid cholesteatoma. Serious intracranial complications may result from the expansion and erosion of the cholesteatoma sac.

Other Ear Care Products

EXTERNAL EAR: EAR CANAL

Ear Wash System

Some patients suffer from a build-up of cerumen in the ear canal, which can result in reduced hearing and prevent the examiner from viewing the tympanic membrane. Ear washing is a proven method to remove cerumen, and is one of the most commonly performed procedures in the primary care office. The Welch Allyn Ear Wash System provides an effective device using suction and irrigation to remove cerumen from patients of all ages. This easy-to-use system allows for cleaner and safer irrigation compared to other methods.



MIDDLE EAR: TYMPANOMETRY

A tympanometer provides the most accurate, objective means of determining middle ear status. Tympanometric results can indicate otitis media with effusion, perforated tympanic membrane, patent tympanostomy tube, ossicular disruption, tympanosclerosis, cholesteatoma, as well as other middle ear disorders.

Welch Allyn MicroTym[®] 2: A portable and compact tympanometric instrument that provides accurate, objective results and printed documentation in seconds.



Welch Allyn TM262[™] AutoTym[®]: A three-in-one instrument that offers tympanometry and ipsilateral acoustic reflex testing, with optional manual audiometry in one convenient, compact design.

INNER EAR: AUDIOMETRY OR OTOACOUSTIC EMISSIONS (OAE)

An audiometer is an electronic instrument for generating sounds that can be used to measure an individual's hearing sensitivity. Audiometric measurement of auditory function can determine the degree of hearing loss, estimate the location of the lesion within the auditory system that is producing the problem, and help establish the cause of the hearing problem.

Welch Allyn AudioScope[®] 3: A portable audiometer to quickly and accurately screen patients at three different levels: 20, 25, and 40 dB, allowing all patients to be screened with a single instrument.



Welch Allyn AM232[™]: A manual audiometer that has the ability to test hearing in ranges beyond speech frequencies. With this instrument, the practitioner can obtain the precise threshold of patients' hearing to better identify specific patterns of hearing loss.

Otoacoustic emissions is a response generated by structures (outer hair cells) in the healthy cochlea to sounds presented into the ear canal. The Welch Allyn OAE Hearing Screener will detect hearing loss, prevent language disabilities and improve patient outcomes. The child-friendly hearing screener is objective, accurate and easy to use.



4341 State Street Road, P.O. Box 220, Skaneateles Falls, NY 13153-0220 USA
(p) 800.535.6663 (f) 315.685.3361 www.welchallyn.com

WelchAllyn[®]

Advancing Frontline Care[™]